



ORIGINAL ARTICLE

Open Access

Ivermectin and *Allium cepa* Protect against Cadmium-Induced Ovarian and Uterine Damage in Adult Wistar Rats

Babatunde Joseph Dare¹, Olawale Olaleye. Obembe², Dolapo Jeminat Azeez¹, Badmus Ismail Abiodun¹, Alabi Peter Dare³, Olabode John Fatoki⁴ Samson Opeyemi Adeleke¹

¹Department of Anatomy, Osun State University, Osogbo, Nigeria

²Department of Physiology Osun State University, Osogbo, Nigeria

³Department of Microbiology, Redeemers' University, Ede, Nigeria

⁴Department of Biochemistry, Osun State University Osogbo, Nigeria

*Correspondence should be addressed to Babatunde Joseph Dare: babatunde.dare@uniosun.edu.ng
Received 19th February 2022; Revised 28th March 2022; Accepted 2nd May 2022

© 2022 Dare et al. Licensee Pan African Journal of Life Sciences an official publication of Faculty of Basic Medical Sciences, Ladoke Akintola University of Technology, Ogbomoso. This is an Open Access article distributed under the terms of the Creative Commons Attribution License (<https://creativecommons.org/licenses/by/4.0>), which permits unrestricted use, distribution, and reproduction in any medium, provided the original work is properly cited.

ABSTRACT

Background: Female reproductive organs are more susceptible to the risk of increased cadmium accumulation. Ivermectin is a known therapeutic drug in general medicine, while *Allium cepa* possesses antioxidant ability. This study investigated the effects of Ivermectin and *Allium cepa* on cadmium-induced ovarian and uterine damage in adult Wistar rats.

Methodology: Twenty-Eight adult female Wistar rats were randomly divided into six groups. Group (A); control group, Group (B); treated with 1.2 mg/kg b.w of Ivermectin, Group (C); treated with 1.2 mg/kg BW of Ivermectin and 2 mg/kg BW Cadmium respectively, Group (D); treated with 2 mg/kg BW Cadmium, Group (E); treated with 2 mg/kg BW Cadmium and 1.5 ml *Allium Cepa* respectively, and Group (F); treated with 1.5 ml *Allium Cepa*. The administration was done orogastrically and daily for four weeks. Animals were euthanized by cervical dislocation twenty- four hours after the last administration, Ovary and Uterus excised following abdominal incision, tissues for histological observation fixed in Bouins' fluid for H/E stain, Masson trichrome, fuelgen stain, and toluidine blue stain respectively. Samples for enzymes assay were homogenized in 5% sucrose solution for lipid peroxidation using; MDA and the antioxidant enzymes using SOD and CAT.

Result: Cadmium treatment exerted oxidative stress, elevated the enzyme markers for oxidative damage in the ovary and uterus, and increased lipid peroxidation leading to cell membrane damage. Histological alterations, degeneration of ovarian follicles, and loss of endometrial lining characterized the animals exposed to cadmium. *Allium cepa* increased the antioxidant enzymes; SOD and CAT while lowering the MDA activities in Cadmium-induced oxidative stress. Histological integrity of the ovary and uterus was maintained; follicular development was evident at various stages, and the endometrial lining integrity was maintained.

Conclusion: This study demonstrated the protective role of *Allium cepa* and Ivermectin against cadmium toxicity on the reproductive organs in female adult Wistar rats

Keywords: Cadmium, Ovary, Uterus, Ivermectin, *Allium cepa*, Fertility.

1. INTRODUCTION

Allium cepa contains sulfur-amino acid, vitamins and minerals, and varieties of secondary metabolites such as phytosterols, flavonoids, and saponins. [1,2,3] *Allium cepa* is highly valued for its therapeutic, antioxidant, antimicrobial, and antidiabetic properties. [4,5] The bulb possessed antiseptic, anthelmintic, antispasmodic, anti-inflammatory, diuretic, carminative, expectorant, hypoglycaemic, febrifuge, lithotriptic, hypotensive, stomachic, and tonic properties [5]. *Allium cepa* (Onions) contain generous amounts of flavonoid quercetin that protect against cataracts, cardiovascular disease, and cancer [6,7]. Ivermectin is potently active against many of internal and external pathogens [8,9]. Ivermectin is effective against a wide range of parasites; gastrointestinal roundworms, lungworms, mites, lice, and horn flies [11-13]. Ivermectin proved to be a 'Wonder drug' in human health, improving nutrition, general health, and wellbeing [14,15]. The growth of various human cancers, such as ovarian cancer (OC), has been completely suppressed by Ivermectin due to its anti-parasitic nature [16-20].

Infertility is a global health issue growing as environmental pollution increases [21-23]. Cadmium (Cd) is a heavy metal known to be an endocrine disruptor [24] and a threat to human fertility health [25]. Diet and smoking are believed to be the primary sources of Cd in the general population [26]. Women are thought to be at greater risk of increased Cd accumulation [27,28] as Cd can accumulate in the ovary. An epidemiological survey reported that Cd in smokers is higher than in nonsmokers [29-31]. Cd directly affects the ovary and uterus, resulting in pathological changes, such as ovarian effusion, bleeding, and atrophies [32]. Cd increases apoptosis and causes cell damage by inducing oxidative stress [33-37].

Cadmium toxicity has been demonstrated in several organs [38-42]. Cd induces tissue injury by creating oxidative stress, [43,44] epigenetic changes in DNA expression, [45-48] and inhibition or upregulation of transport pathways [49,50]. Notably in the proximal S1 segment of the kidney tubule [51,52] inhibition of heme synthesis [53] and impairment of mitochondrial function potentially inducing apoptosis [54]. Depleting glutathione has been observed, as has structural distortion of proteins due to Cd binding to sulfhydryl groups [55-57].

This study investigated the protective effects of Ivermectin and *Allium cepa* on the damaged ovary and uterus of Wistar rats exposed to Cd.

2. METHODOLOGY

2.1 Experimental Animals and Care

Twenty-Eight adult female Wistar rats (143.79-188.29 kg) were used. All animals were obtained and maintained under constant room temperature and humidity (50%), with natural light and dark cycles in the animal facility. The procedures used in this study were approved by the Health Research Institute Ethics Committee (HREC), Osun state university, Nigeria. All animals were given free access to feeding and water provided ad libitum. The animals were acclimatized two weeks before the start of the experiments.

2.2 Ethical Approval

All experimental procedures were performed by the regulations stipulated by the Health Research Ethics Committee College of Health Sciences, Osun State University, Osogbo, Nigeria) complying with the National Institute of Health guide guidelines for the care and use of Laboratory Animals. The study was conducted in the animal testing unit of the Osun State University, Nigeria.

2.3 Administration

Twenty-Eight adult female Wistar rats were randomly divided into six groups. Group A; control group, Group B; treated with 1.2 mg/kg of Ivermectin, Group C; treated with 1.2 mg/kg BW of Ivermectin and 2 mg/kg b.w Cadmium respectively, Group D; treated with 2 mg/kg b.w Cadmium, Group E treated with 2 mg/kg b.w Cadmium and 1.5ml *Allium cepa* respectively, and Group F treated with 1.5ml *Allium cepa*. The administration was done orogastrically and daily for four weeks.

2.4 Animal Sacrifice

Twenty-four hours after administering the last doses, animals were euthanized by cervical dislocation. The ovary and uterus were rapidly removed following an abdominal incision, homogenized at 15 000 rpm, and stored in the refrigerator at -80°C for enzyme assay. The Ovary and Uterus are also fixed in Bouin's fluid for histological parameters.

2.5 Histological Preparation

Each of the excised ovary and uterine tissues were used for histological staining. Fixation was done for 48 hours using 10% neutral bouin's fluid. After fixation had taken place, the tissues were embedded using paraffin wax. Dehydration was done in ascending grades of alcohol; dehydrated tissues were cleared into two changes of xylene. The tissues were infiltrated in two changes of paraffin

wax in the oven at 37% for one hour each and finally embedded mold smeared with glycerin so that paraffin-embedded tissues were trimmed and mounted on a wooden block at a section of 5µm thick on a rotary microtome (Leica RM 2135; Leica Instruments, Germany). The sections were spread in a warm bath and collected on a clean glass slide smeared with egg albumen. The slides were then dried on a glass drying plate at a temperature of 40°C overnight to enviable adherence and thus were stored in racks until it was ready for staining. Each sample had an average of 30 sections from which a systematic random sampling of slices was taken, and stereological and histomorphological analyses were performed.

2.6 Biochemical assay

The homogenized ovary and uterus tissue were utilized for malondialdehyde (MDA), superoxide dismutase (SOD), lactate dehydrogenase (LDH), and Catalase assay. The oxidative stress and bioenergetics markers were assessed by an enzyme-linked immunosorbent assay kit (IBL-America, Minneapolis, Minnesota, USA). Excised ovary and uterus tissues were put in Lao-style mortar containing 1ml of 0.25 Mm (5%) sucrose solutions and were homogenized thoroughly. Tissue homogenate was collected in a 5 ml plain serum bottle for enzyme assay; superoxide dismutase (SOD), Malondialdehyde (MDA), Catalase, and Lactate Dehydrogenase (LDH)

Malondialdehyde levels in tissues were measured according to the protocol outlined Stocks and Dormandy, 1971

[58] and the activity of LDH in the homogenate. The homogenates were centrifuged at 10,000×g for 10 minutes at 4°C. The clear supernatant obtained was used for the measurement of LDH activity. Superoxide dismutase activity in homogenates was determined using the method of Misra and Fridovich [59].

2.7 Statistical analysis

Data collected were analyzed using a one-way analysis of variance (ANOVA) followed by Tukey's (HSD) multiple comparison test with the aid of GraphPad Prism v.6 (GraphPad Software, Inc., La Jolla, CA, USA). Data were presented as means ± SEM (standard error of the mean). $p < 0.05$ was considered statistically significant

3. RESULTS

Table 1 revealed a significant increase in tissue level of MDA in animals exposed to cadmium only, group D. However, animals exposed to cadmium that were treated with Ivermectin in group C and those that were treated with *Allium cepa* in group F demonstrated a significant decrease in the tissue level of MDA activities. Enzymes of carbohydrate metabolism LDH increased in animals that were exposed to cadmium; groups C and D as well as the animals treated with *Allium cepa* only, group F. Oxidative marker enzymes; Catalase, significantly decreased in animals exposed to cadmium only, animals treated with *Allium cepa* only, group F, showed a decrease in catalase activities. However, groups B and ivermectin treated group) showed an increase in catalase activities relative to the animals exposed to *Allium cepa*. Similarly, a significant decrease in tissue level of SOD across all groups; however, animals exposed to *Allium cepa*, group F, showed a significant increase relative to cadmium exposure and the control animals

Table 2 revealed a significant decrease in tissue level of MDA in cadmium induced cadmium-induced animals treated with *Allium cepa*, group E and animals treated with *Allium cepa* only, group F as well as animals treated with Ivermectin in group C. Enzyme activities of carbohydrate metabolism LDH, increased in animals treated with ivermectin only, groups B, and animals treated with cadmium only, group D. *Allium cepa* administration lower the activities of the lactate dehydrogenase in the uterine tissue. Oxidative marker enzymes, Catalase, were

Table 1: Effect of Ivermectin and *Allium cepa* on antioxidant enzymes in Cadmium- Induced ovarian damage

Gr P	MDA (µg/m)	LDH (u/l)	SOD (u/mg)	Catalase (µmol/l)
A	3.71±2.63	1.65±0.92	1.53±0.86*	2.16±1.47
B	3.34±2.76	1.89±0.75	0.76±0.52	3.82±1.74
C	2.60±1.18*	4.07±2.89*	1.23±0.41*	4.81±5.27*
D	4.53±3.21*	2.56±1.48	0.92±0.30	1.42±0.68
E	2.79±1.49	1.64±0.83*	0.09±0.04	3.63 ±2.79
F	2.25±1.20*	4.12±3.84*	3.53±2.84*	0.67±0.25*

*Indicate significant changes, $p \leq 0.05$

significantly higher in the ivermectin-treated group, group B, and alum cepa treated group, group E, relative to the control animals. Similarly, *Allium cepa* treatment

Table 2: Effect of Ivermectin and Allium cepa on antioxidant enzymes in Cadmium Induced Uterine damage.

Grp	MDA [µg/m]	LDH [µ/l]	SOD [µ/mg]	Catalase [µmol/l]
A	4.89±4.10*	3.06±2.51	0.46±0.21	6.00±5.12
B	3.67±3.14*	6.12±5.22*	0.61±0.11	9.39±8.40
C	2.67±2.00	2.06±1.70*	0.15±0.05*	5.24±4.23*
D	2.77±1.91	4.09±3.65	0.61±0.21	8.71±7.65*
E	1.55±1.10	2.27±1.90*	2.46±1.93	10.74±9.50*
F	1.52±1.02*	3.81±3.28	3.07±2.52*	7.36±6.22*

*Indicate significant changes, p≤0.05

in groups groups E and F noticed a significant increase in tissue level of SOD activities relative to the control and ivermectin treated.

3.2 Histological Observation

Histological expression, as shown in figure Figures 1 and 2 stained with H/E, revealed histo-architecture of the ovary and uterus of adult female Wistar rats in the control group and treatment groups. Group A; conrol control animals, group B; Ivermectin treatment and group F; *Allium cepa* treatment only, showed generalised histology of the ovary and uterus, no alterations in the morphological presentation of the ovaries and uterus observed; the ovarian follicles distinctly organized, in primordial follicles, secondary, tertiary/antral follicles, the Graafian follicle (GF) and the Corpus luteum along with the developing oocyte. Normal perimetrium (PE), myometrium (MY), which is characterised characterized by smooth, thick, circular muscles and the less thick longitudinal muscles, endometrium (EN), which contains the endometrial glands lined with cuboidal epithelial, connective tissue cells and matrix, lamina propria and tall columnar cells of the surface epithelium and endometrial lumen (L) expressed. Endometrium revealed no signs of vacuolation. Conversely, Cadmium treatment animals, group D, induced degenerative changes in the ovary, characterised characterized by a reduction in the number of ovarian follicles, necrotic, disorganized Graafian follicle, and degenerated granulosa and theca cells surrounding the mature oocyte in the pre-ovulatory follicle as well as degraded luteal cells. Group C, cadmium-induced treated treatment with ivermectin, showed degenerated oocyte and disorganized granulosa cells even though the developing oocyte was seen in the antral follicle. Group E, *Allium cepa* treated animals, appeared normal, ovarian follicles present, corpus luteum and lutein cells intact.

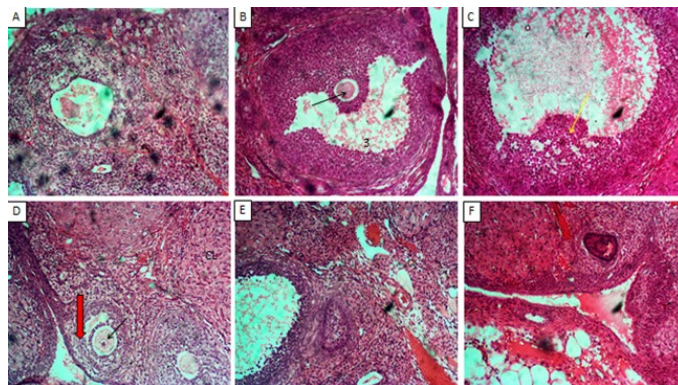


Figure 1: Photomicrographs of the ovary in wistar rats across the various study groups. Hematoxylin and Eosin stain (x100). A= Control; demonstrated mature graafian follicles, associated with the theca internal and external and the presence of oocytes B= Ivermectin only;well preserved ovarian cortex with the presence of mature follicles, antrum formation and the oocytes presence; the black arrow. C =Ivermectin + Cadmium; degeneration/ loss of oocytes, arrest of follicular development as well as degenerated theca layers of the mature follicles D = Cadmium only; arrest of follicular development, presence of corpus luteum and absence of thsec follicules were evident E = allium Cepa + Cadmium. 1 = Primary follicle; 2 = secondary follicle; 3 = Tertiary follicle; GF = Graafian follicle; CL = Corpus luteum; Black arrow = Developing oocyte; V = Vacuole.

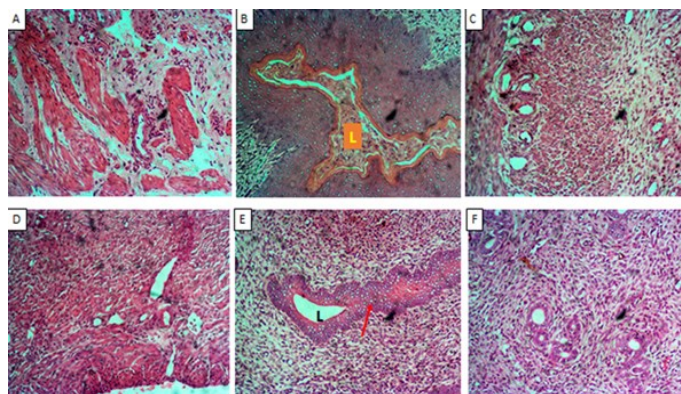


Figure 2: Photomicrographs of uterine sections of adult Wistar rats across the various experimental groups. H/E (x100). A = Control Endometrium well developed, with the associated endometrial gland; B = Ivermectin only Endometrial lined with coulumnar epithelium and well developed endometrial layer; C = Ivermectin + Cadmium mild to moderate changes in the endometrial lining, and intact endometrial glands ; D = Cadmium only reduced endometrial lining and loss of endometrial glands; E = Allium Cepa + Cadmium; F = Allium cepa only endometrial integrity preserved .

Animals treated with Cadmium presented a thick, dense, distorted, and degenerated endometrium and loss of cells of the columnar epithelium compared to the control animals' uterus. Ivermectin-only treated group showed necrosis in the endometrium and degeneration in the ad-luminal epithelium associated with eosinophilic debris in the lumen compared to control.

Figures 3 and 4 revealed Ivermectin-only (B) and Cadmi-

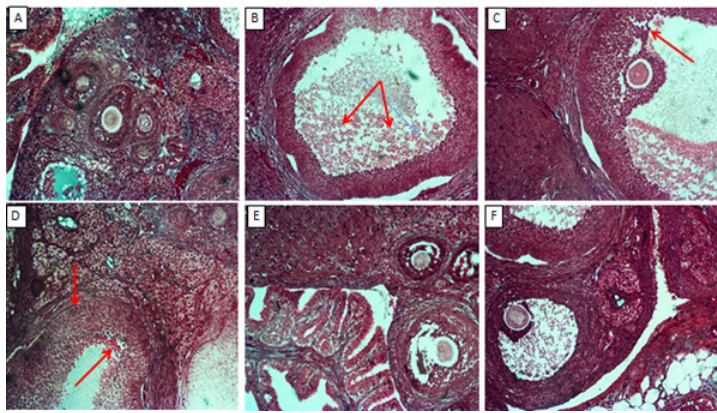


Figure 3: Photomicrographs of the ovary in wistar rats across the various study groups. Masson Trichrome stain (x100). A = Control Presence of the developing follicles at various stages and the well preserved connective tissue parenchyma; B = Ivermectin only similar to the control group observation and well preserved theca layers; C = Ivermectin + Cadmium preserved ovarian architecture; D = Cadmium only reduced developing follicles and degenerated connective substances; E = *Allium Cepa* + Cadmium and *Allium cepa* only; Group F = demonstrated folliculars development at various stages and preserved connective theca layers .

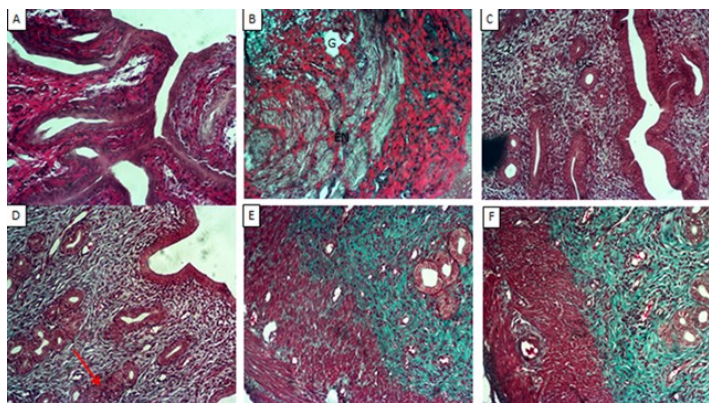


Figure 4: Representative photomicrographs of the uterine sections in Wistar rats across the various experimental groups. Masson trichrome stain (x100). A = Control preserved lining of the endometrial lining and connective tissue moderately stained; B = Ivermectin only demonstrated more endometrial glands; C = Ivermectin + Cadmium; D = Cadmium only reduced the endometrial glands and loss of the endometrial glands lining; E = *Allium Cepa* + Cadmium; F = *Allium cepa* only preserved uterine integrity .

um-only treated groups (C) had reduced number of ovarian follicles, suggesting fibrosis. Animals in group A, control, demonstrated follicles at the various stages of development along the ovarian cortex. Number of ovarian follicles present in Group E appeared normal. All treated groups demonstrated increased increase in collagen in the endometrial stroma and slightly between the smooth muscle fibers; though these features are not so pronounced in the control rats. *Allium cepa* treated groups showed distorted and diffused endometrium and luminal epithelium, and degeneration of cuboidal epithe-

lium of some endometrial glands was noticed in group D.

Figures 5 and 6 showed Ivermectin-only treated group was characterized by irregular-shaped follicles, Cadmium-only; cadmium-only treated group had a reduced number of ovarian follicles and a few atretic follicles. *Allium cepa*-treated groups had no significant changes in histomorphological appearance when compared to control. Flattened/squamitized epittraumatized helium of endometrial glands in groups B, C, and D are well expressed.

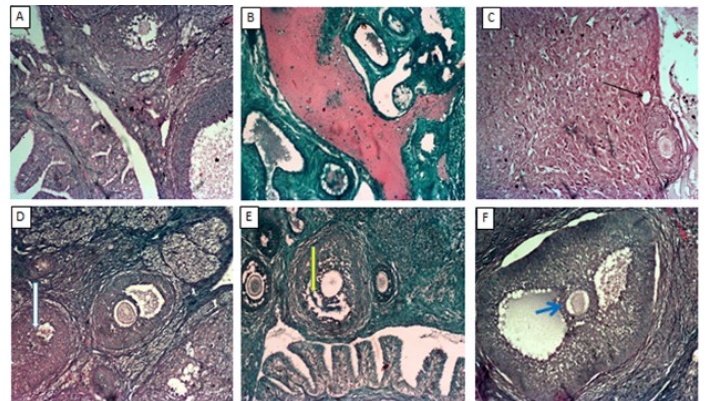


Figure 5: Photomicrographs of the ovary in wistar rats across the various study groups. Fuelgen stain (x100). A = Control; B = Ivermectin only; C = Ivermectin + Cadmium; D = Cadmium only; E = *Allium Cepa* + Cadmium. Evidence of continuous cell division across the control, ivermectin and allium cepa treatment indicated by the development of follicles at various stages

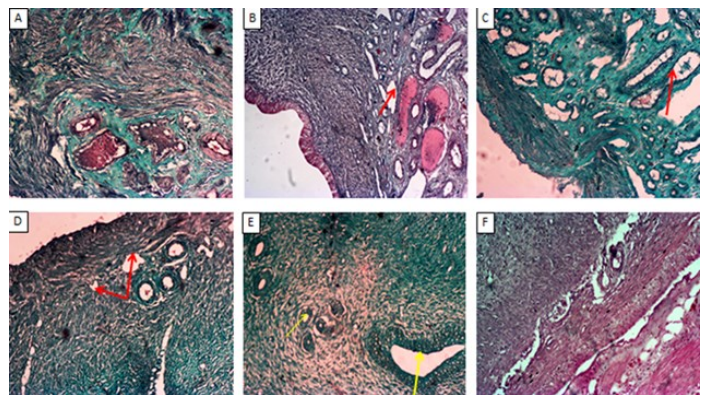


Figure 6: Shows the representative photomicrographs of the uterine sections in wistar rats across the various experimental groups. Fuelgen stain (x100). A = Control; B = Ivermectin only; C = Ivermectin + Cadmium; D = Cadmium only; E = *Allium Cepa* + Cadmium; F = *Allium cepa* only. Evidence of continuous cell division along the epithelia lining and along the cell lining of the endometrial glands, however, cadmium treatment showed loss of continuous cell division and reduced endometrial glands

In figures 7 and 8, the control group presents ovarian follicles, corpus luteum, and numerous capillaries along the cortex. Cadmium-only treated group showed atretic cor-

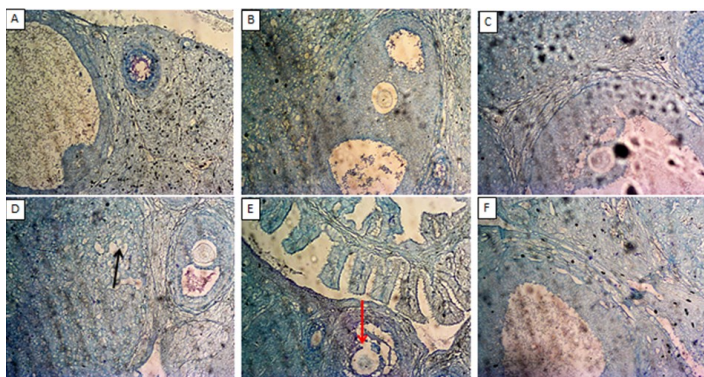


Figure 7: Photomicrographs of the ovary in Wistar rats across the various study groups. Toluidine blue stain (x100). A = Control; B = Ivermectin only; C = Ivermectin + Cadmium; D = Cadmium only; E = *Allium Cepa* + Cadmium. Black arrow = vacuole; Red arrow = Degenerating cells of zona pellucida.

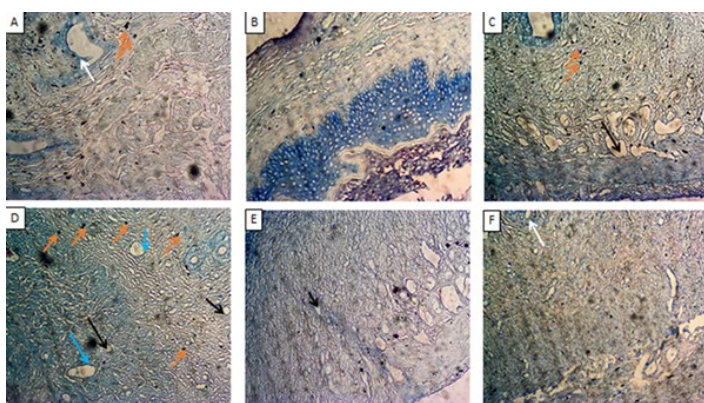


Figure 8: Shows the representative photomicrographs of the uterine sections in wistar rats across the various experimental groups. Toluidine Blue stain (x100). A = Control; B = Ivermectin only; C = Ivermectin + Cadmium; D = Cadmium only; E = *Allium Cepa* + Cadmium; F = *Allium cepa* only.

pus luteum with vacuolation. A degeneration and reduction in cells of zona pellucida of the antral follicle was seen in group E but only a slight reduction in a number of capillaries when compared to control. There are no histopathological changes in ovarian follicles, capillaries, and corpus luteum of experimental group which received *Allium cepa* treatments compared to the control group. The cadmium-only treatment group showed a reduced number of endometrial glands and degeneration of gland epithelium, vacuolation, and increased mast cells compared to the control. However, vacuolations were also expressed in animals treated with Ivermectin and cadmium.

4. DISCUSSION

This study reported a significant decrease in the activities of ovarian and uterine antioxidant enzymes among the animals treated with a higher dosage of Cd, the result is

consonant with that of Nna et al., [59] who noted cadmium treatment reduced the activities of antioxidant enzymes (LDH, SOD, and CAT), consequently promoting oxidative stress. Superoxide dismutase and catalase had been known to provide a defense line against reactive oxygen and nitrogen species consequently a potential anti-oxidant. Oxidative stress triggers apoptosis in the majority of germ cells within the ovary and even in ovulated oocytes [60]. Also, oxidative stress in the follicular fluid deteriorates oocyte quality and reduces reproductive outcome [61, 62]. Concurrently, combined treatment of Cd with *Allium cepa* caused increased in levels of antioxidant enzymes. This is most-likely due to the antioxidant activity of *Allium cepa* [63]. *Allium cepa* have also been recently found to reduce MDA levels and increase SOD and CAT levels. Kumar et. al., [64] and Atakisi et al., [65] reported ivermectin induced free radicals damage and decreased antioxidant enzyme activity, and Khawla [66] reported that Ivermectin caused an increase in MDA levels and reduced antioxidant enzymes to cause oxidative stress in rabbits.

Cadmium administration in Wistar rats caused a significant decrease in the activities of Malondialdehyde, Lactate dehydrogenase, Superoxide dismutase, and Catalase in the ovary and uterus of adult Wistar rats. Cadmium had been shown to have potential endocrine disruptors, according to Hanson, [67] who reported cadmium as a developmental toxicant in the reproductive system.

This study revealed ivermectin-treated animal demonstrated necrosis in the endometrial lining, coupled with degenerated luminal epithelium. Cadmium administration promotes abnormal follicular growth, cell death, follicular damage, and tumours [68-71]. These reports have been in agreement with the result obtained in this study; atretic follicles, arrest of follicular development, and degeneration of ovarian cortex were reported in this study in line with the reports of Golubnitschaja et. al., [72] and Markowska [73] that showed the combating effects of ivermectin against human cancers, including ovarian cancer. This study revealed that uterine lining Cd treated animals characterised by thick, dense, distorted, and degenerated endometrium and loss of cells of the columnar epithelium in line with previous reports [74, 75].

Histological assessment confirmed Cd's impact in the ovarian damage, Cd induced reduction in the number of follicles, degradation of the corpus luteum, and disorganized Graafian follicles. Different treatments with ivermectin and *Allium cepa* had no adverse effects on morphological representation of the ovary thus, no histo-

pathological effects were noticed, although combined treatment of rats with Cd and ivermectin did not prove entirely effective in this category as a degenerated oocyte and follicle was seen in the Cd and ivermectin treated. Conversely, co-treatment of Cd and *Allium cepa* showed that *Allium cepa* mitigated the effects of Cd on the ovary. These findings agreed with the report of Gunnarsson et al., [76], which showed antioxidant action of zinc administration against cadmium toxicity in testicular tissue.

Cadmium treatment caused fibrosis characterized by a reduced number of ovarian follicles, degeneration, and reduction in granulosa cells of the Graafian follicle when compared to control. Changes in granulosa cells of tertiary follicle were also noticed in ivermectin and Cd treated group; this is in line with the works of Chatterjee et al., [77], and Ferramola et al., [78] that demonstrated apoptotic promoting effects of Cd by arresting cell cycle formation as well as the histological alteration in the myocardium. On the other hand, *Allium cepa* treatments had no reduction in the number of ovarian follicles and the number of ovarian follicles present in rats treated with *Allium cepa* and Cd appeared normal. This implies that *Allium cepa* was enough to mitigate the effects of Cd on the cytoarchitecture of the ovary in agreement with the stated health benefits of *Allium cepa* [5].

Fuelgen stain for DNA deposition in which Cd treated group had reduced number of ovarian follicles and a few atretic follicles. Ivermectin-treated group characterized by irregular-shaped follicles and *Allium cepa*-treated groups had no significant changes in histomorphological appearance compared to control. The presence of collagen in the endometrial stroma and slightly between the smooth muscle fibers were observed in Cd-treated animals.

Distorted and diffused endometrium and luminal epithelium were noticed in the ivermectin treated group, and degeneration of cuboidal epithelium of some endometrial glands was noticed. No other significant histomorphological changes were noticed in the layers and epithelial cells of all treated groups compared to control. *Allium cepa* and Cd treatment group showed normal cuboidal epithelium in the gland of the endometrium, however, in Cd-only treated group, reduction in the number of endometrial glands and degeneration of gland epithelium, vacuolation, and accumulation of mast cells evident. These histopathological changes were not noticed in the *Allium cepa* treatment groups. However, vacuolations were also expressed in the ivermectin and Cd treated group and luminal con-

gestion in the ivermectin-only treated group. Ivermectin-treated groups showed little or no significant histopathological changes when compared to control. Treatment with *Allium cepa* and ivermectin were both effective in attenuating the effects of Cd on the cytoarchitecture of the ovary and uterus.

In conclusion, Cd readily accumulates and spreads through tissues, including the ovary and uterus, causing hormonal disruption and ovarian damage and affecting fertility. This study counteractively explored the effects of ivermectin and *Allium cepa* on cadmium-induced ovarian and uterine damage. *Allium cepa* administration was more effective in attenuating the effects of cadmium on the uterine and ovarian morphology, much more than the anti-parasitic agent Ivermectin.

Conflict of Interest

The authors declare that there is no conflict of interest.

Authors Contributions

BJD conceived and designed the study; contributed to data analysis and wrote the paper; **OOO, FOJ, OSA** Collected data, performed analysis, and wrote the paper; **JDA, AIB, PAD** Collected data, contributed to data analysis

REFERENCES

1. Ríos, JL.; Recio, MC. Medicinal plants and antimicrobial activity. *J. Ethnopharmacol.* 2005; 100: 80–84.
2. Dorman, HJ.; Deans, SG. Antimicrobial agents from plants: Antibacterial activity of plant volatile oils. *J. Appl. Microbiol.* 2000; 88: 308–316.
3. Batiha, GS.; Beshbishy, AM.; Tayebwa, DS.; Adeyemi, OS.; Shaheen, H.; Yokoyama, N.; Igarashi, I. Evaluation of the inhibitory effect of ivermectin on the growth of Babesia and Theileria parasites in vitro and in vivo. *Trop. Med. Health.* 2019; 47: 42.
4. Batiha, GS.; Alkazmi, LM.; Wasef, LG.; Beshbishy, AM.; Nadwa, EH.; Rashwan, EK. *Syzygium aromaticum* L. (Myrtaceae): Traditional uses, bioactive chemical constituents, pharmacological and toxicological activities. *Biomolecules.* 2020; 10: 202.
5. Griffiths, G., Trueman, L., Crowther, T., Thomas, B., Smith, B. Onions—a global benefit to health. *Phytother Res.* 2002; 16 (7): 603–615.
6. Izawa, H., Kohara, M., Aizawa, K., Suganuma, H., Inakuma, T., Watanabe, G., Taya, K., Sagai, M. Alleviative effects of Quercetin and Onion on male reproductive toxicity induced by Diesel exhaust particles. *Biosc. Biotech. Biochem.* 2008; 72 (5): 1235–1241.

7. Jeje, SO., Akpan EE., Kunle-Alabi, OT., Akindele, OO., Raji, Y. Protective role of *Allium cepa* Linn (onion) juice on maternal dexamethasone induced alterations in reproductive functions of female offspring of Wistar rats. *Current Research in Physiology*. 2021; 145–154
8. Geary, TG. Ivermectin 20 years on: maturation of a wonder drug. *Trends Parasitol*. 2005; 21 (11): 530–532.
9. Del Giudice P, Marty P. Ivermectin: A new therapeutic weapon in dermatology. *Arch Dermatol* .1999; 135:705-6.
10. Burg, RW., Miller, BM., Baker, EE., Birnbaum, J., Currie, SA., Hartman, R., Kong, YL., Monaghan, RL., Olson, G., Putter, I., Tunac, JB., Wallick, H., Stapley, EO., Oiwa, R. and Ōmura, S. Avermectins, new family of potent anthelmintic agents: producing organisms and fermentation. *Antimicrob. Agents Chemother*. 1979; 15 (3): 361–367.
11. Campbell, WC., Fisher, MH., Stapley, EO., Albers-Schönberg, G. and Jacob, TA. (1983) Ivermectin: a potent antiparasitic agent. *Science*. 1983; 221: 823–828.
12. Burg, RW. and Stapley, EO. Isolation and characterization of the producing organism. In *Ivermectin and Abamectin* (ed. Campbell, W.C.). Springer, New York, 1989; pp. 24–32.
13. Graefe EU, Wittig J, Mueller S. Pharmacokinetics and bioavailability of quercetin glycosides in humans. *J. Clin.Pharmacol* 2001; 41:492–499.
14. Chabala, JC, Mrozik, H., Tolman, RL, Eskola, P., Lusi, A., Peterson, LH, Woods, MF, Fisher, MH. and Campbell, WC. Ivermectin, a new broad-spectrum antiparasitic agent. *J. Med. Chem*. 1980; 23: 1134–1136.
15. Panahi Y, Poursaleh Z, Goldust M. "The efficacy of topical and oral ivermectin in the treatment of human scabies" *Annals of Parasitology*. 2015; 61 (1): 11–16.
16. Ottesen, E. and Campbell, W. Ivermectin in human medicine. *J. Antimicrob. Chemother*. 1994; 34: 195–203.
17. Gallardo F, Mariame B, Gence R, Tilkin-Mariame AF. Macrocyclic lactones inhibit nasopharyngeal carcinoma cells proliferation through PAK1 inhibition and reduce in vivo tumor growth. *Drug Des Devel Ther*. 2018; 12:2805–14.
18. Patel BC, Ostwal S, Sanghavi PR, Joshi G, Singh R. Management of malignant wound myiasis with ivermectin, albendazole, and clindamycin (triple therapy) in advanced head-and-neck cancer patients: a prospective observational study. *Indian J Palliat Care*. 2018; 24:459–64.
19. Diao H, Cheng N, Zhao Y, Xu H, Dong H, Thamm DH. Ivermectin inhibits canine mammary tumor growth by regulating cell cycle progression and WNT signaling. *BMC Vet Res*. 2019; 15: 276.
20. Markowska A, Kaysiewicz J, Markowska J, Huczynski A. Doxycycline, salinomycin, monensin and ivermectin repositioned as cancer drugs. *BMC Vet Res*. 2019; 29:1549–54.
21. Phillips KP, Foster WG. Key developments in endocrine disrupter research and human health. *J Toxicol Environ Health B Crit Rev* 2008; 11:322– 344.
22. Wang J, Xu Y, Wan H, Hu J. Antibiotic ivermectin selectively induces apoptosis in chronic myeloid leukemia through inducing mitochondrial dysfunction and oxidative stress. *BiochemBiophys Res Commun*. 2018;497:241–7.
23. Liu J, Wang W, Zhu J, Li Y, Luo L, Huang Y, Zhang W. Di (2-ethylhexyl) phthalate (DEHP) influences follicular development in mice between the weaning period and maturity by interfering with ovarian development factors and microRNAs. *Environ Toxicol* 2018; 33:535–544.
24. Adams SV., Newcomb, P.A and White, E. "Dietary cadmium and risk of invasive postmenopausal breast cancer in the VITAL cohort," *Cancer Causes and Control*, 2012; 23 (6):845–854.
25. Jamal M, Ghaffari MA, Hoseinzadeh P, Hashemitabar M, Zeinali M. Human sperm quality and metal toxicants: protective effects of some flavonoids on male reproductive function. *Int. J. Fertil Steril* 2016; 10:215– 223.
26. Mallozzi M, Leone C, Manurita F, Bellati F, Caserta D. Endocrine disrupting chemicals and endometrial cancer: An overview of recent laboratory evidence and epidemiological studies. *Int J Environ Res Public Health* 2017; 14:E334.
27. Vesey DA, Gobe GC. Current health risk assessment practice for dietary cadmium: data from different countries. *Food Chem Toxicol* 2017; 106:430–445.
28. Zhu Y, Li Z, Pang Y, Huo W, Li N, Li Z, Zhang J, Ye R, Wang B. Association between chronic exposure to tobacco smoke and accumulation of toxic metals in hair among pregnant women. *Biol Trace Elem Res* 2018; 4(2):14
29. Richter PA, Bishop EE, Wang J, Swahn MH. Tobacco smoke exposure and levels of urinary metals in the U.S. youth and adult population: the National Health and Nutrition Examination Survey (NHANES) 1999–2004. *Int J Environ Res Public Health* 2009; 6:1930– 1946.
30. Suprewicz K, Kozikowska I, Chrobaczynska-Dylag M, Gał A, Piekarczyk A, Sikora J, Sławska H, Stawarz R. Effects of the cigarette smoking on the newborn clinical parameters and the accumulation of cadmium and lead in the placenta of women from Upper Silesia. *Ginekol Pol* 2013; 84:776– 780.
31. Massanyi P1, Toman R, Valent M, Cupka P. Evaluation of selected parameters of a metabolic profile and levels of cadmium in reproductive organs of rabbits after an experimental administration. *Acta Physiol Hung* 1995; 83:267– 273.
32. Wang XJ, Xiong GP, Luo XM, Huang SZ, Liu J, Huang XL, Xie YZ, Lin WP. Dibutyl phthalate inhibits the effects of Follicle-Stimulating hormone on rat granulosa cells through down-regulation of follicle-stimulating hormone receptor. *Biol Reprod* 2016; 94:144.
33. Zhang W, Jia H. Effect and mechanism of cadmium on the progesterone synthesis of ovaries. *Toxicology* 2007; 239:204–212.
34. Wang L. and E. P. Gallagher, "Role of Nrf2 antioxidant defense in mitigating cadmium-induced oxidative stress in the olfactory system of zebrafish," *Toxicology and Applied Pharmacology*. 2012; 266(2):177–186.
35. Wang J, Xu Y, Wan H, Hu J. Antibiotic ivermectin selectively induces apoptosis in chronic myeloid leukemia

- through inducing mitochondrial dysfunction and oxidative stress. *BiochemBiophys Res Commun.* 2018; 497:241–7.
36. Nna VU, Usman UZ, Ofutet EO, Owu DU. Quercetin exerts preventive, ameliorative and prophylactic effects on cadmium chloride - induced oxidative stress in the uterus and ovaries of female Wistar rats. *Food Chem Toxicol* 2017; 102:143–155.
 37. Wang, Y.; Wang, X.; Wang, Y.; Fan, R.; Qiu, C.; Zhong, S.; Wei, L.; Luo, D. Effect of Cadmium on Cellular Ultrastructure in Mouse Ovary. *Ultrastruct. Pathol.* 2015, 39, 324–328.
 38. Xu C, Baillymaitre B, Reed J C. Endoplasmic reticulum stress: cell life and death decisions. *J Clin Invest* 2005; 115:2656–2664.
 39. Cobo I, Martinelli P, Flandez M, Bakiri L, Zhang M, Carrillo-de-Santa- ´ Pau E, Jia J, Sanchez-Ar ´ evalo Lobo VJ, Meg ´ ´ias D, Felipe I, Del Pozo N, Millan I et al. Transcriptional regulation by NR5A2 links differentiation ´ and inflammation in the pancreas. *Nature* 2018; 554:533–537.
 40. Shao CC, Nan L, Zhang ZW, Su J, Li S, Li JL, Xu SW. Cadmium supplement triggers endoplasmic reticulum stress response and cytotoxicity in primary chicken hepatocytes. *Ecotoxicol Environ Saf* 2014; 106:109–114.
 41. Fabrizio G, Di Paola S, Stilla A, Giannotta M, Ruggiero C, Menzel S, KochNolte F, Sallese M, Di Girolamo M. ARTC1-mediated ADP-ribosylation of GRP78/BiP: a new player in endoplasmic-reticulum stress responses. *Cell Mol Life Sci* 2015; 72:1209–1225.
 42. Jin Y, Zhang S, Tao R, Huang J, He X, Qu L, Fu Z. Oral exposure of mice to cadmium (II), chromium (VI) and their mixture induce oxidative- and endoplasmic reticulum -stress mediated apoptosis in the livers. *Environ Toxicol* 2016; 31:693–705.
 43. Cuypers A., M. Plusquin, T. Remans et al., “Cadmium stress: an oxidative challenge,” *BioMetals.* 2010; 23(5): 927–940.
 44. Matovic V., A. Buha, Z. Bulat, and D. Dukic-Cosic, “Cadmium ´ toxicity revisited: focus on oxidative stress induction and interactions with zinc and magnesium,” *Arhiv za Higijenu Rada iToksikologiju.* 2011; 62(1); 65–76.
 45. Luparello C., R. Sirchia, and A. Longo, “Cadmium as a transcriptional modulator in human cells,” *Critical Reviews in Toxicology.* 2011; 4(1) 75–82.
 46. Martinez-Zamudio R. and Ha H. C., “Environmental epigenetics in metal exposure,” *Epigenetics.* 2011; 6(7): 820–827.
 47. Hansen, KR; Knowlton, NS; Thyer, AC; Charleston, JS; Soules, MR; Klein, NA. "A new model of reproductive aging: the decline in ovarian non-growing follicle number from birth to menopause" *Hum Reprod.* 2008;23(3): 699–708
 48. Wang B., C. Shao, Y. Li, Y. Tan, and L. Cai, “Cadmium and its epigenetic effects,” *Current Medicinal Chemistry.* 2012; 19(16): 2611–2620.
 49. Van Kerkhove E., V. Pennemans, and Q. Swennen, “Cadmium and transport of ions and substances across cell membranes and epithelia,” *BioMetals.* 2010; 23(5) 823–855,
 50. Wan L. and Zhang H., “Cadmium toxicity: effects on cytoskeleton, vesicular trafficking and cell wall reconstruction,” *Plant Signaling & Behavior.* 2012; 7(3):345–348.
 51. Vesey D. A., “Transport pathways for cadmium in the intestine and kidney proximal tubule: focus on the interaction with essential metals,” *Toxicology Letters.* 2010; 198 (1): 13–19.
 52. Hanson ML., Brundage, KM, Schafer, R, Tou, JC and Barnett, J.B. “Prenatal cadmium exposure dysregulates sonic hedgehog and Wnt/´-catenin signaling in the thymus resulting in altered thymocyte development,” *Toxicology and Applied Pharmacology.* 2010; 242(2):136–145.
 53. Schauder A., Avital, A and Malik, Z. “Regulation and gene expression of heme synthesis under heavy metal exposure— review,” *Journal of Environmental Pathology, Toxicology and Oncology* 2010; 29(2):137–158.
 54. Cannino G., Ferruggia, E, Luparello, C and Rinaldi, A.M. “Cadmium and mitochondria,” *Mitochondrion.* 2009; 9 (6):377–384.
 55. Valko M., Morris, H and Cronin, MT. “Metals, toxicity and oxidative stress,”*Current Medicinal Chemistry.* 2005;12(10):1161–1208.
 56. Whittaker MH Wang, G, Chen, QZ “Exposure to Pb, Cd and As mixtures potentiates the production of oxidative stress precursors,” *Toxicology and Applied Pharmacology.* 2011;254(2)154–166.
 57. Wang T, Yuan Y, Zou H, Yang J, Zhao S, Ma Y, Wang Y, Bian J, Liu X, Gu J, Liu Z, Zhu J. The ER stress regulator Bip mediates cadmium-induced autophagy and neuronal senescence. *Sci Rep* 2016; 38(6):091.
 58. Stocks, J. and Dormandy, T. (1971) The Autoxidation of Human Red Cell Lipids Induced by Hydrogen Peroxide. *British Journal of Haematology*, 20, 95-111.
 59. Nna VU, Ujah GA, Mohamed M, Etim KB, Igba BO, Augustine ER, Osim EE. Cadmium chloride-induced testicular toxicity in male wistar rats; prophylactic effect of quercetin, and assessment of testicular recovery following cadmium chloride withdrawal. *Biomed Pharmacother.* 2017; 94:109-123. doi: 10.1016/j.biopha.2017.07.087. Epub 2017 Jul 27. PMID: 28756368.
 60. Pandey, A., Tripathi, A., Premkumar, K., Shrivastav, T., Chaube, S. Reactive oxygen and nitrogen species during meiotic resumption from diplotene arrest in mammalian oocytes. *J. Cell. Biochem.* 2010; 111: 521–528.
 61. Tiwari, M., Prasad, S., Tripathi, A., Pandey, A., Singh, A., Shrivastav, T., Chaube, S., 2016. Involvement of reactive oxygen species in meiotic cell cycle regulation and apoptosis in mammalian oocytes. *Reactive Oxygen Species.* 2016; 1: 110–116
 62. Ebbesen, S., Zachariae, R., Mehlsen, M., Thomsen, D., Hojgaard, A., Ottosen, L., 2009. Stressful life events are associated with a poor in-vitro fertilization (IVF) outcome: a prospective study. *Hum. Reprod.* 2009; 24: 2173–2182
 63. Lee BK, Jung YS: *Allium cepa* extract and quercetin protect neuronal cells from oxidative stress via PKC-ε inacti-

- vation/ERK1/2 activation. *Oxid Med Cell Longev* 2016; 24(9); 24.
64. Kumar Sampath KP, Debjit BC, Biswajit PT. *Allium cepa*: A traditional medicinal herb and its health benefits. *J. Chem. Pharm. Res.*, 2010;2(1): 283-291
65. Atakisi E, Atakisi O, Topcu B, Uzun M. Effects of therapeutic dose of ivermectin on plasma nitric oxide and total antioxidant capacity in rabbits. *Eur Rev Med Pharmacol. Sci.* 2009;13(6):425-9.
66. Khawla BN, Ala Al-Deen H, Eman A. Effects of Ivermectin on Lipid Profiles, Antioxidant Enzymes and Proteins with the Beneficial Effects of Vitamin C in Rabbits. *International Journal for Sciences and Technology.* 2015; 10(3) 94-100.
67. Hanson ML, Holaskova, I Elliott, M. "Prenatal cadmium exposure alters postnatal cell development and function," *Toxicology and Applied Pharmacology.* 2012;261(2):196–203.
68. Satarug, S, Garrett, SH, Sens, MA, Sens, DA. Cadmium, Environmental Exposure, and Health Outcomes. *Environ. Health Perspect.* 2010; 118: 182–190.
69. Ramos-Treviño, J.; Bassol-Mayagoitia, S.; Hernández-Ibarra, JA.; Ruiz-Flores, P.; Nava-Hernández, MP. Toxic effect of cadmium, lead, and arsenic on the Sertoli cell: Mechanisms of damage involved. *DNA Cell Biol.* 2018; 137: 600–608.
70. Capcarová, M.; Harangozó, L.; Árvay, J.; Tóth, T.; Gabriny, L.; Binkowski, ŁJ.; Palšová, L.; Skalická, M.; de la Luz Garcia Pardo, M.; Stawarz, R. Essential and xenobiotic elements in cottage cheese from the Slovak market with a consumer risk assessment. *J. Environ. Sci. Health Part B* 2020; 55: 677–686.
71. Sallet, ML.; Diaw, AD.; Gningue-Sall, D.; Aaron, SE.; Aaron, JJ. Toxic heavy metals: Impact on the environment and human health, and treatment with conducting organic polymers, a review. *Environ. Sci. Pollut. Res. Int.* 2020; 27: 27–42.
72. Golubnitschaja O, Costigliola V. General report & recommendations in predictive, preventive and personalised medicine. White paper of the European Association for Predictive, Preventive and Personalised Medicine. *EPMA J.* 2012;3:14.
73. Markowska A, Kaysiewicz J, Markowska J, Huczynski A. Doxycycline, salinomycin, monensin and ivermectin repositioned as cancer drugs. *BMC Vet Res.* 2019;29:1549–54.
74. Johnson MD, Kenney,N, Stoica., A "Cadmium mimics the in vivo effects of estrogen in the uterus and mammary gland," *Nature Medicine.* 2003;9(8):1081–1084.
75. Prozialeck WC, Edwards, JR and Woods, J.M "The vascular endothelium as a target of cadmium toxicity," *Life Sciences.* 2006; 79(16):1493–1506.
76. Gunnarsson D., Svensson, M, Selstam, G and Nordberg, G. "Pronounced induction of testicular PGF2 α and suppression of testosterone by cadmium-prevention by zinc," *Toxicology.* 2004; 200(1): 49–58.
77. Chatterjee S., Kundu, S. Sengupta, S, and Bhattacharyya, A. "Divergence to apoptosis from ROS induced cell cycle arrest: effect of cadmium," *Mutation Research.* 2009; 663 (1-2): 22– 31.
78. Ferramola ML, Perez Diaz, MF, Honore, SM "Cadmium-induced oxidative stress and histological damage in the myocardium," *Toxicology and Applied Pharmacology.* 2012; 265(3):380–389, 2012.